

Vascular lab report
Assessed by: Emily Blake (cvs)

Name	Hospital No	Date of Exams: 22/02/2019
DOB:	NHS No:	Ip/Op: OP
Refer:	Hospital S	

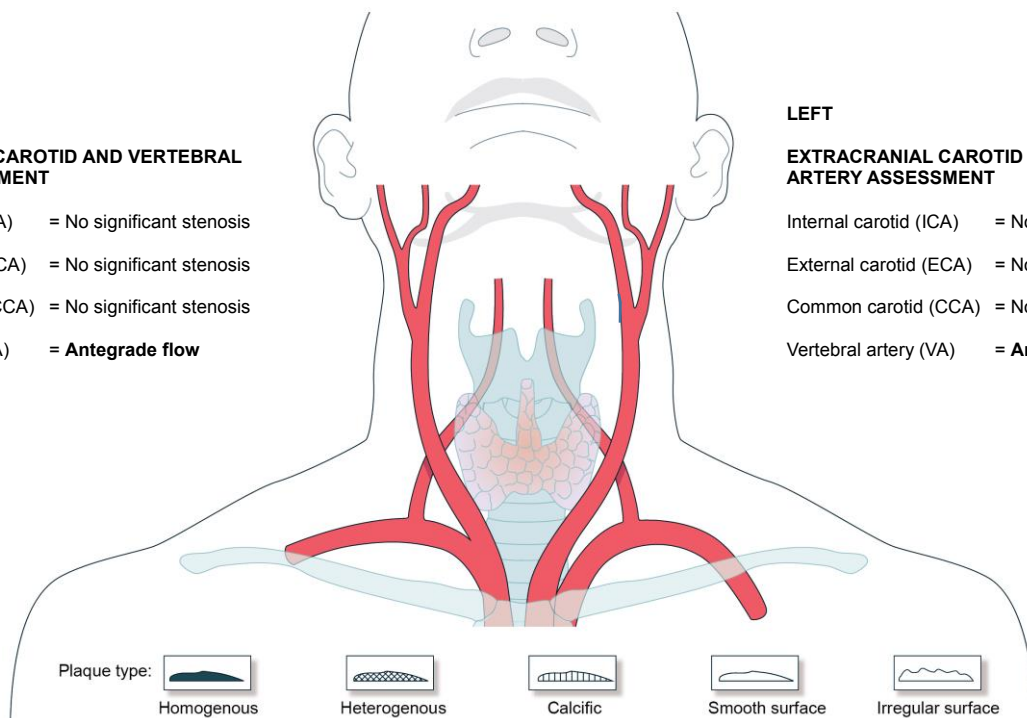
Clinical Indications: Syncope ? CAS

Carotid and Vertebral Artery – Duplex scan
RIGHT
EXTRACRANIAL CAROTID AND VERTEBRAL ARTERY ASSESSMENT

Internal carotid (ICA) = No significant stenosis
 External carotid (ECA) = No significant stenosis
 Common carotid (CCA) = No significant stenosis
 Vertebral artery (VA) = **Antegrade flow**

LEFT
EXTRACRANIAL CAROTID AND VERTEBRAL ARTERY ASSESSMENT

Internal carotid (ICA) = No significant stenosis
 External carotid (ECA) = No significant stenosis
 Common carotid (CCA) = No significant stenosis
 Vertebral artery (VA) = **Antegrade flow**


Report:
RIGHT:

The Common (CCA), Internal (ICA) and External (ECA) carotid arteries are patent with no significant stenosis detected.

ICA Peak Systolic Velocity (PSV) = 0.51m/sec (Normal = <1.20m/sec)

ICA End Diastolic Velocity (EDV) = 0.15m/sec (Normal = <0.40m/sec).

The Vertebral artery is patent with antegrade blood flow detected.

LEFT:

The Common (CCA), Internal (ICA) and External (ECA) carotid arteries are patent with no significant stenosis detected (>=50%). Minimal amount of atheroma imaged in the bulb and proximal internal carotid artery.

ICA Peak Systolic Velocity (PSV) = 0.37m/sec (Normal = <1.20m/sec)

ICA End Diastolic Velocity (EDV) = 0.09m/sec (Normal = <0.40m/sec).

The Vertebral artery is patent with antegrade blood flow detected.



Conclusion:

Patent carotid and vertebral arteries with no haemodynamically significant stenosis detected bilaterally.
Of note there are several prominent lymph nodes noted within the neck bilaterally, the largest on the right measures 27x10mm and on the left 21x7mm.